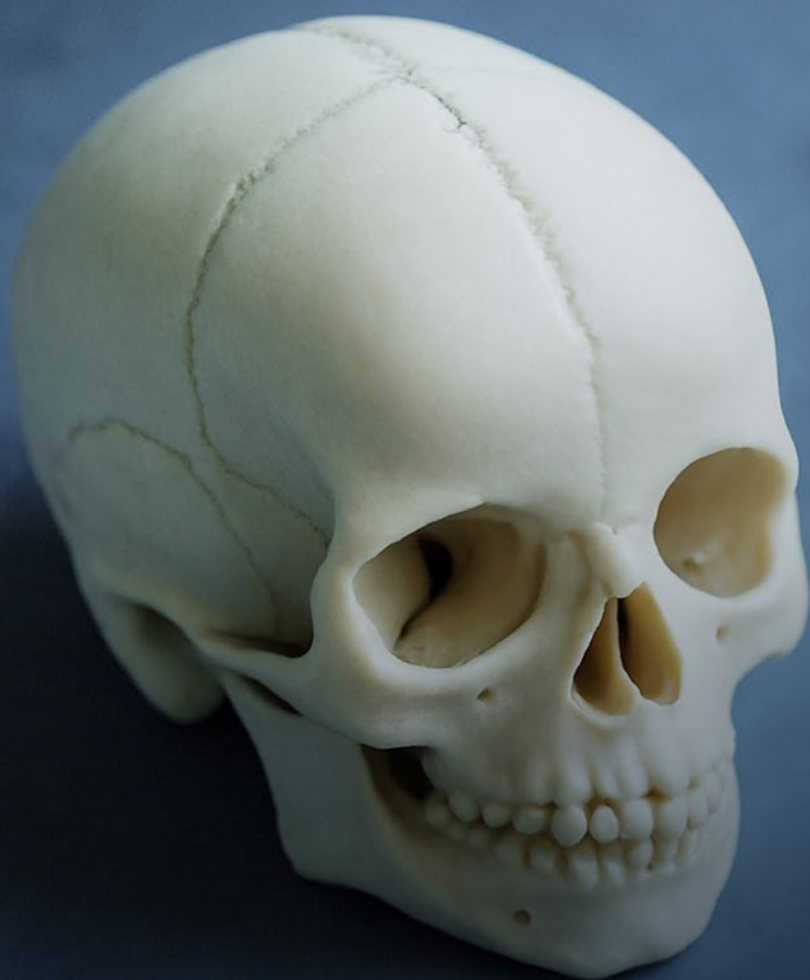

International Society of Craniofacial Surgery

# ISCFS NEWSLETTER

Volume 3 | Number 1



## IN THIS ISSUE:

CONGRESS AWARDS

ORTHODONTIC CORNER

**MY WAY:** HOW I TREAT  
LATE-PRESENTING SAGITTAL  
CRANIOSYNOSTOSIS

JANUARY 2026

# MESSAGE FROM THE EDITOR

## Colleagues and friends,

As we have turned the page on another year, I would like to extend my warmest wishes to the entire International Society of Craniofacial Surgery community for a healthy, productive, and fulfilling New Year. This moment of transition offers a natural opportunity for reflection, and it is difficult to do so without feeling a strong sense of optimism about the momentum of our Society.

That optimism is rooted in the extraordinarily positive energy generated by our recent biennial Congress in Shanghai. The meeting was marked not only by scientific rigor and technical excellence, but also by a palpable sense of engagement, curiosity, and collegiality. Across plenary sessions and informal conversations, there was a shared enthusiasm for advancing our field - through innovation, thoughtful debate, and a continued commitment to improving outcomes for patients with craniofacial differences around the world. The strength of the discussions and the diversity of perspectives reaffirmed the unique value of ISCFS as a truly global professional home.

Equally inspiring was the spirit of connection that permeated the congress. New collaborations were formed, longstanding relationships were renewed, and the next generation of craniofacial surgeons was clearly visible and actively engaged. That collective energy does

not end when the meeting adjourns; rather, it carries forward into our clinical work, research endeavors, educational missions, and society initiatives throughout the coming years.

As we begin the New Year, I encourage all members to remain actively involved - by contributing to future webinars, sharing insights through the newsletter "My Way" column, mentoring colleagues, encouraging membership in the ISCFS, and continuing to push the boundaries of what is possible in craniofacial surgery. Together, we have an opportunity to build on this momentum and to shape the future of our field with purpose and integrity.

On behalf of the editorial team, thank you for your dedication to ISCFS. I wish you and your families a happy New Year and look forward to all that we will accomplish together in the year ahead.

Sincerely,



**JESSE TAYLOR**

ISCFS Secretary-Treasurer  
UNITED STATES

Volume 3 | Number 1

# TABLE OF CONTENTS

Message from the Editor Jesse Taylor	02
Message from the President Irene Mathijssen	03
Window Into History Riccardo F. Mazzola	04
MY WAY Joseph Firriolo, Mark M. Urata, Susan Durham, Alexis Johns, Irene M. J. Mathijssen, Sarah L. Versnel, Mieke M. Pleumeekers, Marie-Lise C. van Veelen	06
Survey Suhas Udayakumaran, Pramod Subhash	11
Congress Awards	13
Young Surgeons' Experience Janina Kueper, Hanna Lif	14
Neurosurgery Corner Jay Jayamohan	20
Orthodontic Corner Hitesh Kapadia, Marielena Layuno Matos, Srinivas Susarla Srinivas, Richard Hopper	22
New Members	28
Event Calendar	30

# MESSAGE FROM THE PRESIDENT

## Dear members of the Society,

The year 2025 has ended and we look back at a wonderful and unique meeting in Shanghai under the guidance of the host and Past-President Xiongzheng Mu. It is very valuable to share knowledge and expertise, but getting together and meeting in person is key. The best ideas for collaboration develop over coffee breaks. The preparations for the upcoming meeting from September 7th to 10th 2027 in Rotterdam are already done. We can again rely on the professional assistance of Barbara Boeld, Catherine Foss and Verena Reinmuth from the Boeld team.

A little history about the city of Rotterdam: In the 13th century, the lands around the Rotte River were governed by nobles. They built protective dikes to guard against frequent sea floods and as a result Rotterdam developed. Its position close to the sea was a big advantage and boosted the transportation of goods and the development of the port. The number of inhabitants was 50,000 in the 18th century and increased to 600,000 in 1940, with a high population density.

World War I and the 1929 Depression hit the city hard, causing poverty and unemployment. May 14, 1940, was the darkest day in Rotterdam's history. During the German invasion, the city was

bombed and burned for three days, with fires lasting more than two months. Reconstruction commenced in the 50's and offered architects the opportunity to redesign a city from scratch. Modern buildings were erected among the few that survived the bombing, creating a mixture of styles. The city's motto, "Stronger Through Struggle" reflects the spirit that continues to define the city today.

The team from Rotterdam is eager to welcome you to our city. Meanwhile, the society will keep you up to date with interesting news and webinars. We can only grow and become stronger as a society with your help and input. Next to that, we need to include the new generation of surgeons. So please encourage your fellows and residents to join our community and contribute to shaping its future. If you have suggestions to strengthen their participation in our society and meeting in 2027, please let us know. Team work makes us strong during clinical practice, but also in advancing our society.

I wish you all the best for 2026.

**Irene Mathijssen** -  
President  
The Netherlands



**IRENE MATHIJSEN**  
ISCFS President  
THE NETHERLANDS

*"Our goal is to increase the impact that we can make for our patients and joining forces will deliver this."*

---

# WINDOW INTO HISTORY

## PIERRE ROBIN AND THE SYNDROME THAT BEARS HIS NAME

**Pierre Robin** (1867-1950) was a prominent French stomatologist who studied medicine at Paris University. He became professor at the French School of Stomatology, and from 1914, the editor-in-chief of the *Revue de Stomatologie*. He was a prolific writer.

**The syndrome of micrognathia and glossoptosis** - In a series of articles, beginning in 1923, Robin described the combined condition of hypoplasia of the mandible and glossoptosis.<sup>1</sup>

His first papers reported clinical observations in young adults who had small jaws, associated with upper airway obstruction during sleep. To solve this problem, Robin proposed maintaining the lower jaw forward and mouth open through the use of special dental splints. Specifically, he invented a novel device named the *Monobloc*.

He demonstrated that in adults, small mandibles lead to a series of both local dental and malocclusion effects, as

well as wider systemic medical problems, including the development of what came to be known as Obstructive Sleep Apnoea.

In 1929, he published a book entitled *La glossoptose. Un grave danger pour nos enfants* (Glossoptosis. A severe danger for our children), simultaneously issued by two printers: Ash and Co., and Gaston Doin.<sup>2</sup> (Figure 1)

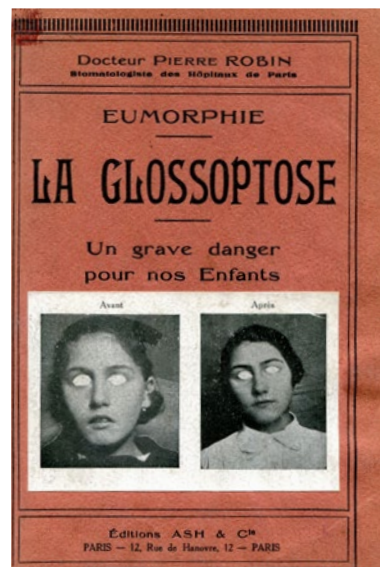

Figure 1 - Title page of P. Robin book *La glossoptose. Un grave danger pour nos enfants*. Paris, Ash and Co. 1929



**RICCARDO F. MAZZOLA**

History Editor  
ITALY

*"He considered the condition part of a vast group of congenital cranial deformities"*



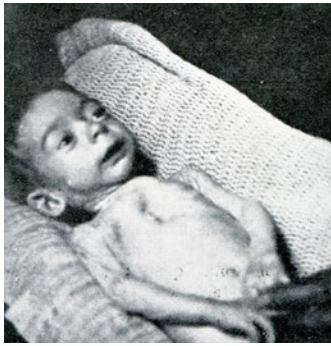

Figure 2 - Thoracic retraction (sternum excavatum) with every inspiration, associated with malnutrition. (from Ref. 2)

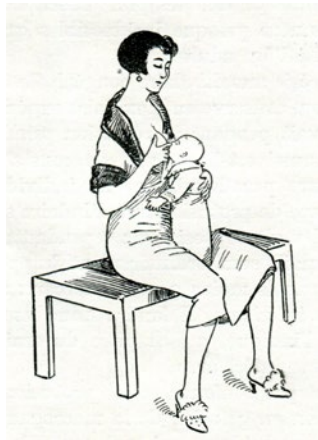

Figure 3 - Orthostatic feeding (from Ref. 2) Apert E., ref. No. 3).

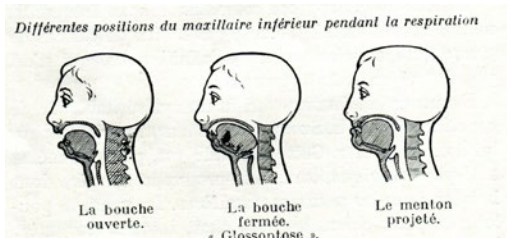


Figure 4 - Different jaw positions during breathing. The central illustration shows the dramatic situation of the tongue against the epiglottis completely impairing respiration (from Ref. 2)



Figure 5 - Spontaneous mandibular development (from Ref. 2)

Chapter two is dedicated to glossoptosis in the newborn and to fractioned orthostatic feeding (*la glossoptose des nourrissons. La tétée orthostatique fractionnée*). Robin pioneered the understanding of the dramatic consequences that micrognathia that he named *atrésie mandibulaire* associated with the condition that glossoptosis may cause: *obstruction respiratoire basse* (low respiratory obstruction); malnutrition, due to complications in feeding; spontaneous or unexpected infant death during sleep, also called Sudden Infant Death Syndrome. He recognised that in such infants breathing difficulties arise due to pressure of the tongue against the epiglottis. Dyspnea, respiratory distress, cyanosis, and thoracic retraction (*sternum excavatum*) with every inspiration, leading to delayed physical and mental development, represent the typical feature of this condition. (Figure 2)

Robin noticed that upper airway obstruction is dramatically more common when these babies lie on their backs. To avoid the "fallen tongue" (glossoptosis) effect, he recommended the orthostatic fractioned treatment during and after feeding. (Figure 3) Fractioned nutrition

means that the newborn takes a short rest after five or six minutes of breastfeeding. Orthostatic positioning, and placement of the infant prone (tummy lying) during sleep so that the tongue and the jaw drop forward, prevents aspiration of mucus and regurgitation of food.

Robin believed that children with this problem, if not properly treated, seldom lived beyond 8 months (Figure 4), but great improvement in airway maintenance may be obtained if the mandible can be moved forward. For this, he suggested early orthodontic treatment. Mandibular development occurs spontaneously in a postero-anterior direction solving the problem of these dramatic breathing difficulties. By four to six years of age the profile becomes almost normal. (Figure 5)

Curiously, Robin did not record cleft palate associated with the hypoplastic mandible, but only high palatal vault.

To honor the stomatologist Robin, who clearly described and identified the rare and dramatic condition of hypoplasia of the mandible and glossoptosis, the condition was termed Pierre Robin Syndrome.<sup>3</sup>

## REFERENCES

1. Robin P. La chute de la base de la langue considérée comme une nouvelle cause de gêne dans la respiration naso-pharyngienne (glossoptosis, considered the most likely cause of impairment during naso-pharyngeal breathing). *Bull Acad Med Paris*. 1923; 89:37-41.
2. Robin P. *La glossoptose. Un grave danger pour nos enfants (Glossoptosis. A severe danger for our children)*. Paris; Ash and Co., n.d. (but. 1929)
3. Randall P, Krogman WM, Jahina S. Pierre Robin and the Syndrome that bears his name. *Cleft Palate J*. 1965; 2: 237-246.

# MY WAY: HOW WE TREAT LATE- PRESENTING SAGITTAL CRANIOSYNOSTOSIS

## LATE-PRESENTING SAGITTAL CRANIOSYNOSTOSIS: THE CHLA EXPERIENCE



**JOSEPH FIRRIOLO**  
UNITED STATES



**MARK M. URATA**  
UNITED STATES



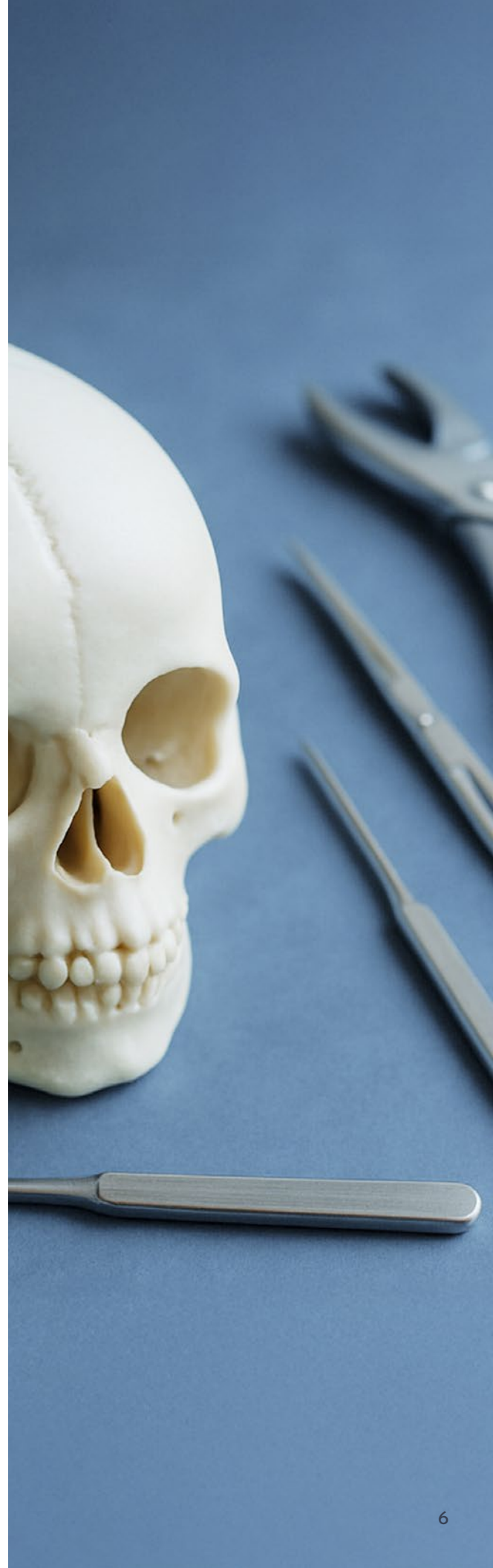**SUSAN DURHAM**  
UNITED STATES



**ALEXIS JOHNS**  
UNITED STATES

Of all cranial sutures, the sagittal suture is most commonly implicated in craniosynostosis. At our institution, isolated sagittal synostosis cases account for 38% of all craniosynostosis operations performed over the past decade. Several

factors may contribute to the delayed presentation of sagittal craniosynostosis. In our recent publication in *PRS Global Open*, Area Deprivation Index (ADI) percentile and public insurance status were significantly associated with an older age at



presentation. Specifically, patients with public insurance were nearly twice as likely to present after four months of age (OR=1.90,  $p=0.002$ ).<sup>1</sup> Delayed presentation may also result from late referral by primary care providers or delayed recognition by the caregiver, particularly in cases where the suture fusion is mild, cranial shape abnormalities are subtle, or the child is otherwise asymptomatic.

What constitutes late presentation and late surgical repair is not universally defined. At our center, both are defined as occurring after 12 months of age, as prior literature indicates that head circumference and cranial length reach approximately 87% of their final growth by this time. Surgical algorithms and long-term outcomes for patients undergoing operative intervention beyond 12 months also remain incompletely characterized. Importantly, a distinction must be made between procedures performed for morphologic correction and those for functional indications, which include evidence of increased intracranial pressure (ICP) and ophthalmologic findings such as papilledema and optic nerve atrophy.

All patients referred to our craniosynostosis center with suspected or confirmed craniosynostosis undergo comprehensive evaluation by our craniosynostosis team, which includes specialists in craniofacial surgery, neurosurgery, ophthalmology, psychology, and pediatrics. When prior imaging is not available, diagnostic imaging is often performed to confirm suture fusion and assess morphology,

as well as associated intracranial abnormalities. However, at times, imaging is deferred due to the obvious presentation of synostosis and to avoid exposing the patient to unnecessary radiation. Periodic ophthalmologic surveillance is also routinely performed to screen for papilledema and optic nerve atrophy.

*"Our experience shows the importance of individualized, multidisciplinary evaluation that balances functional risk and aesthetic considerations."*

At our institution, neuroimaging and ophthalmologic findings serve as the primary determinants of surgical candidacy in late-presenting sagittal craniosynostosis, as they identify patients at risk for functional sequelae related to elevated intracranial pressure or visual compromise. In the absence of such findings, surgical decision-making is individualized and is based on potential psychosocial implications of marked abnormal appearance balanced with the potential risks of operating on an older child.

Although the authors do not employ distinct surgical techniques strictly based on age at intervention, the thickness of the bone along with the decreased pliability of the brain present technical challenges in older patients. Because of this, marked

dimensional changes become progressively more difficult in children undergoing operation after 12 months of age. These age-related technical considerations further inform surgical decision-making and underscore the diminishing cranial remodeling potential with advancing age.

Our understanding of the relationship between neurodevelopment and single suture synostosis is still evolving. Reassuringly, a study from our center has shown that there has not been any association between age of repair and development; however, 91% of this patient cohort underwent operation at <12 months of age.<sup>2</sup> As such, it is essential that all late-presenting patients are referred for developmental evaluation.

If imaging and ophthalmologic exams are clear and the patient remains asymptomatic, cranial vault remodeling is generally not recommended unless the calvarial deformity is severely abnormal. Instead, these patients are monitored annually by neurosurgery, plastic surgery, and ophthalmology for any functional changes until the age of six, at which cranial growth plateaus. Those with mild to moderate deformity may undergo camouflage operations extracranial with fat grafting, onlay bone grafts, or implants. This surveillance-based approach allows for timely intervention should functional concerns arise. Families that elect to participate can complete neurodevelopmental evaluations at ages 7, 10, and 14 years to receive updated recommendations across

school, home, and community settings at key developmental stages.

To contextualize this algorithm within our institutional experience, we reviewed all patients evaluated in our outpatient craniofacial clinic over the past decade for sagittal craniosynostosis. Of 329 patients with confirmed sagittal synostosis, 26 (7.9%) initially presented after 12 months of age, with a mean age at presentation of 1.62 years (12.1 months to 7.9 years). Of these patients, 17 had photos taken at the time of presentation, with a mean cephalic index of  $74.76 \pm 6.66$ .

Five of these patients (19.2%) underwent operation for sagittal craniosynostosis, with a mean cephalic index of  $70.59 \pm 4.57$ . Three of the five patients underwent surgical repair for morphology before 24 months of age. One patient demonstrated optic nerve atrophy on ophthalmologic exam and underwent immediate cranial vault remodeling at approximately 18 months. The final patient reported receiving cranial vault remodeling between 5 to 6 years of age at an outside institution, for which no symptomatic indication was mentioned in their medical record. Notably, one patient received surgical correction of hyperopia with simultaneous lumbar

puncture for increased ICP by ophthalmology at 2.3 years of age without cranial vault remodeling.

For the remaining 21 patients managed nonoperatively, the majority were initially referred for evaluation of abnormal head shape and subsequently diagnosed with sagittal synostosis ( $n=18$ ). Three patients initially evaluated between 12 and 18 months of age were recommended for operative correction of the cranial shape rather than functional indications; however, some were lost to follow-up ( $n=1$ ) or re-presented several months later ( $n=2$ ), at which time surgical intervention was no longer advised due to them being beyond the surgeons' recommended age for reconstruction.

Our experience shows the importance of individualized, multidisciplinary evaluation that balances functional risk and aesthetic considerations. We aim to identify patients who stand to benefit most from intervention while safely observing those who do not. As referral patterns, sociodemographic factors, and family priorities continue to influence the timing of presentation, a thoughtful and data-informed approach remains essential for delivering equitable, patient-centered care to this cohort.

## REFERENCES

1. Jolibois MI, Roohani I, Moshal T, et al. Sociodemographic Factors Associated with Delayed Presentation in Craniosynostosis Surgery at a Tertiary Children's Hospital. *Plast Reconstr Surg Glob Open*. 2024;12(8):e6035. Published 2024 Aug 30. doi:10.1097/GOX.0000000000006035
2. Johns AL, McComb JG, Urata MM. Early Longitudinal Development in a Diverse Prospective Cohort with Sagittal, Unicoronal, or Metopic Craniosynostosis. *Cleft Palate Craniofac J*. Published online April 30, 2025. doi:10.1177/10556656251337268



# MY WAY: HOW WE TREAT LATE-PRESENTING SAGITTAL CRANIOSYNOSTOSIS



**IRENE M. J. MATHIJSEN**  
THE NETHERLANDS



**SARAH L. VERSNEL**  
THE NETHERLANDS



**MIEKE M. PLEUMEEKERS**  
THE NETHERLANDS



**MARIE-LISE C. VAN VEELEN**  
THE NETHERLANDS

Children with sagittal craniosynostosis who present at or before the age of 6 months are treated with spring expansion. Those who present later used to be scheduled for a fronto-biparietal correction. Besides the widening of the biparietal area, we corrected the forehead by tilting it backward to correct the frontal bossing.

There is a fair amount of evidence in literature that frontal bossing in sagittal synostosis corrects by itself with time. Also, 6- to 18-year-old children who underwent a fronto-biparietal correction, including the setback of the forehead, indicated that they would like to change the shape of their forehead (Kurniawan et al., 2024). Children of the same age who underwent a strip-craniectomy, in which the forehead is not included, did not express this desire. This made us change our protocol and perform only a biparietal expansion for patients with sagittal synostosis that present after the age of 6 months.

#### **SURGICAL TECHNIQUE:**

A straight incision is made over the back of the head, as this part remains hair bearing for the longest time in males. The skin flaps are developed to expose the coronal and lambdoid sutures.

The periosteum is incised in an H-shape, allowing both temporal muscles to be pulled downward on a caudal pedicle. In planning the osteotomies, we routinely preserve both coronal and lambdoid sutures to allow future skull growth. The dura is left attached to the coronal and lambdoid sutures. Both parietal bones are taken out, as well as a 4-cm wide bone strip including the closed sagittal suture. The osteotomies on the sides are made just above the squamosal suture. Two bone wedges are excised on the cranial side of the parietal bones and one bone wedge is excised on the caudal side of the parietal bones to allow bending of the bones. The bone edges at the cranial side are sutured together with vicryl to make the parietal bones more curved. The parietal bones are sutured back in place with some overlap with the temporal bones to widen the skull at the

---

*"This made us change our protocol and perform only a biparietal expansion for patients with sagittal synostosis that present after the age of 6 months."*

temporal area. The sagittal bone strip is adapted in shape with the Tessier plier and returned in place to cover the sagittal venous sinus. Only in case of a rigid saddle deformity that cannot be corrected sufficiently, a small excision of this area is performed. A sonic weld plate is positioned on top of the vault to fix the cranial edges of the parietal bones to the sagittal bone strip. This plate determines the degree of widening of the skull. The plate is positioned away from the skin incision to reduce the risk of infection. The anterior and posterior edges of the parietal bones are trimmed, to allow a smooth transition to the frontal and occipital bone. The left-over bone pieces are fixed with vicryl sutures to close the gaps in front and behind the parietal bones and to close the gaps next to the sagittal bone strip. Bone dust is collected during the procedure and placed within the smaller gaps that remain and then covered with tissue glue. A low-vacuum wound drain is inserted and the wound is closed in two layers with vicryl and vicryl rapid. Wound coverage is done with a paraffin dressing and a bandage. The following morning, the drain and bandage are removed.

After surgery, the patient is placed in supine position, with the head positioned in between two rolled towels that are fixed in a terry cloth holder (Van Veelen et al., 2015). The rigid fixation with sonic weld does allow the children to sleep on the side of the head, but sleeping on the back of the head is advised for the first two to three weeks after surgery.

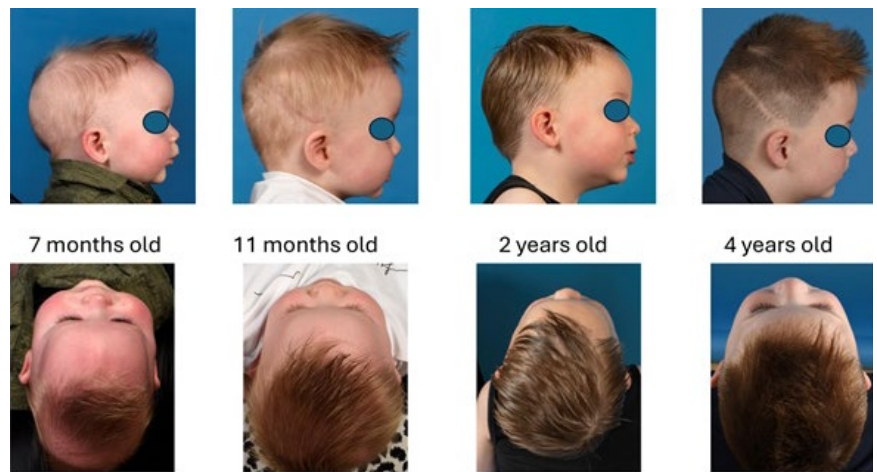

Figure 1 - Side and top view of boy with sagittal synostosis preoperatively at 7 months of age and postoperatively at various ages. A biparietal expansion was performed at the age of 8 months.

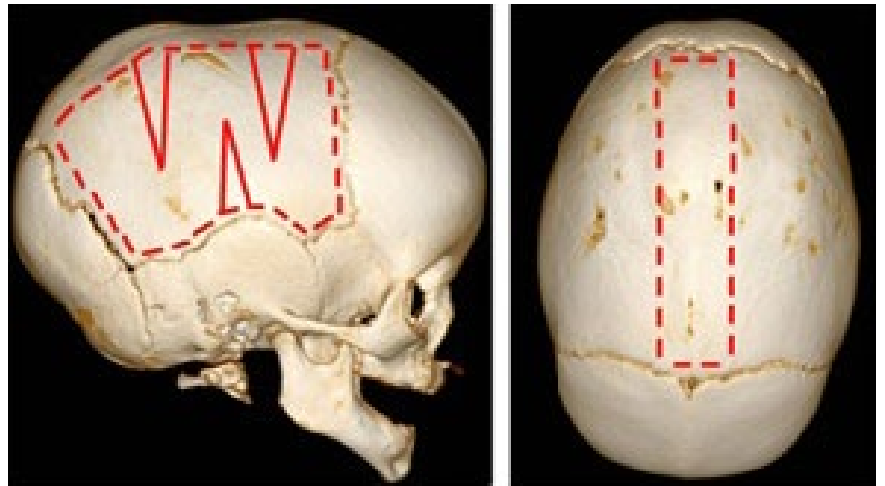


Figure 2 - Preoperative 3D CT-scan. The osteotomies of the parietal bones, the design of the wedges and 4-cm wide sagittal bone strip are illustrated.

## REFERENCES

- Kurniawan MSIC, Kamst NW, Mathijssen IMJ, Erler NS, van Veelen MC. Child-Patient Perspective on Results After Correction of Sagittal Synostosis and the Difference Between Child-Patient and Parent's Perspectives. *J Craniofac Surg.* 2024 Jun 1;35(4):1040-1044.
- Van Veelen ML, Bredero HH, Dirven CM, Mathijssen IM. Effect of Presurgical Positioning on Skull Shape in Sagittal Suture Synostosis. *J Craniofac Surg.* 2015 Sep;26(6):2012-4.

# CHAOS TO FLOW:

## THE CASE FOR A FUNCTIONAL TAXONOMY IN CRANIOSYNOSTOSIS



**SUHAS UDAYAKUMARAN**  
INDIA



**PRAMOD SUBHASH**  
INDIA

### THE PARADOX — WHAT IS NOT IN THE NAME?

The clinical management of craniosynostosis is undeniably complex, characterized by diverse phenotypes and functional challenges. Yet, despite this variability, our treatment goals are remarkably uniform.

---

*"An expert sees a forest over trees."*

Ander Ericsson, psychologist and author of *Peak: Secrets from the New Science of Expertise*

---

*Why, then, is our language so fragmented?*

Currently, the nomenclature we use to describe our workflow is chaotic. We rely on a mix of descriptors - phenotype (e.g., brachycephaly), genotype (e.g., Apert), suture involvement, or syndromic status. While these terms describe the pathology, they do not provide insight into the management process or the patient's functional status.

### A NECESSARY EVOLUTION

Currently, our specialty is lost in trees. We lack a standardized nomenclature that comprehensively represents the condition across multiple disciplines involved in care <sup>1,2</sup>. Evolution in nosology is not unique to our specialty <sup>1,2</sup>.

Drawing parallels to other complex fields, such as Neuro-oncology, the WHO classification for CNS tumors has faced and adapted to criticism <sup>3</sup>, just as the International Classification of Diseases (ICD-5) has evolved to become more granular and useful despite controversies over implementation <sup>4</sup>. Craniofacial surgery requires a similar evolution. We need a nomenclature that depicts functional status at every stage of care.

### OUR PROPOSAL

In our recent publications, we proposed a "Nomenclature and Problem Mapping" framework - a fluid concept that shifts the paradigm from static labelling to dynamic workflow management <sup>5,6</sup>. Because this approach challenges convention, it requires validation through extensive experience of the global craniofacial community.

**YOUR ROLE: FROM CHAOS TO FLOW**

To ensure that this nomenclature is robust and universally applicable, we request your input and feedback on these issues and our work on nomenclature<sup>5,6</sup> via the survey we have developed.

**CLICK HERE** to participate.

Beyond the jargon, our goal is simple: to clear the "nosological chaos" and establish clear objectives for optimal patient management. This is the first step toward that clarity.

**REFERENCES**

1. Golinko MS, Berry JG, Proctor M, Bonfield CM, Meara JG. New ICD-10 Diagnosis Codes to Improve Craniosynostosis Classification. *Plast Reconstr Surg Glob Open*. 2023;11(11):e5440.
2. Gonzalez SR, Light JG, Golinko MS. Assessment of Epidemiological Trends in Craniosynostosis: Limitations of the Current Classification System. *Plast Reconstr Surg Glob Open*. 2020;8(3):e2597.
3. Gielen GH, Baugh JN, van Vuurden DG, Veldhuijzen van Zanten SEM, Hargrave D, Massimino M, et al. Pediatric high-grade gliomas and the WHO CNS Tumor Classification-Perspectives of pediatric neuro-oncologists and neuropathologists in light of recent updates. *Neurooncol Adv*. 2022;4(1):vdac077.
4. World Health Organization. International statistical classification of diseases and related health problems (ICD) 2024 [Available from: <https://www.who.int/standards/classifications/classification-of-diseases>. Accessed.
5. Udayakumar S, Panikar D, Subhash P. Chaos to Flow: Categorization, Nomenclature to Problem Mapping: Unified Interdisciplinary Language in Craniosynostoses. *J Craniofac Surg*. 2025.
6. Udayakumar S, Panikar D, Subhash P. Defining a Taxonomical Map for Craniosynostoses: An Integrated Nomenclature for Interdisciplinary Workflow and Problem Mapping in Craniosynostoses Management: A Feasibility Study. *J Craniofac Surg*. 2022.

# PHOTO GALLERY 21<sup>ST</sup> ISCFS CONGRESS



Discover all the highlights of the 21<sup>st</sup> ISCFS CONGRESS. Click the button below to explore the full image gallery and download your favorite moments.

**PHOTO GALLERY**



# CELEBRATING EXCELLENCE AT THE 21<sup>ST</sup> ISCFS INTERNATIONAL CONGRESS

The 21<sup>st</sup> ISCFS International Congress held in Shanghai, China in October once again highlighted the spirit of innovation, scientific rigor, and clinical excellence that defines our community. We are proud to announce the recipients of the Congress's prestigious distinctions: the TESSIER LECTURE, MARCHAC AWARD, and BEST POSTER AWARD.



President Mu  
with Dr. Arnaud

## TESSIER LECTURE

Eric Arnaud, France



Chao Peng

## BEST POSTER AWARD

**Gas Metabolite Patterns to Identify Oral Squamous Cell Carcinoma**

Chao Peng, Guoran Li, Minyi Ren, Le Yang - Hospital of Stomatology, Sun Yat-sen University, Guangzhou, China



Zhixuan Sun

## MARCHAC AWARD

**Mechanical force-induced oncostatin M secretion by Jun-positive neutrophils promotes craniofacial bone regeneration for midface hypoplasia treatment**

Zhixuan Sun<sup>1</sup>, Yujie Chen<sup>2</sup>, Pengbing Ding<sup>1</sup>, Zheng Wang<sup>1</sup>, Zhiyu Lin<sup>3</sup>, Binyi Zhou<sup>1</sup>, Fengyi Hu<sup>4</sup>, Enhang Lu<sup>1</sup>, Haibo Xiang<sup>1</sup>, Xin Yang<sup>1</sup>, Peiyang Zhang<sup>1</sup>, Hongsen Bi<sup>1</sup>, Zhenmin Zhao<sup>1</sup>

<sup>1</sup>Department of Plastic Surgery, Peking University Third Hospital, Beijing, China. <sup>2</sup>Department of Plastic Surgery, Peking University People's Hospital, Beijing, China. <sup>3</sup>Department of Plastic Surgery and Regenerative Medicine, Fujian Medical University Union Hospital, Fujian, China.

<sup>4</sup>Department of Sports Medicine, Peking University Third Hospital, Beijing, China

These honors recognize outstanding scientific contributions, visionary research, and lifelong dedication to advancing craniofacial and facial surgery. The award-winning presentations and lectures set a high standard and sparked inspiring discussions throughout the Congress. We warmly congratulate all winners on their exceptional achievements and their meaningful impact on our field.

As we reflect on an outstanding 21<sup>st</sup> Congress, we also look ahead with great anticipation to our 22<sup>nd</sup>.

**SAVE THE DATE:** The next ISCFS International Congress will take place in Rotterdam, The Netherlands, on **September 7-10, 2027**. We look forward to welcoming the global ISCFS community for another unforgettable exchange of knowledge, innovation, and collaboration.

# YOUNG SURGEONS' EXPERIENCE

## MY PATH TO CRANIOFACIAL SURGERY

*"The face remains, to me, one of the most compelling frontiers in medicine: where development, technology, culture, and humanity meet."*



**JANINA KUEPER**  
UNITED STATES

From my earliest exposure to biology, I have been fascinated by development: how complex structures arise from simple beginnings, and how minute changes can lead to profound differences in form and function. The human face, in particular, captured my attention early on. It is simultaneously anatomical, genetic, social, and symbolic. Over time, this fascination matured into a commitment to craniofacial

surgery, a field that sits uniquely at the intersection of development, identity, and repair.

My formal training began in Berlin, where I completed my medical degree at the Charité University of Medicine. Alongside clinical training, I pursued basic science research in tissue engineering at the Berlin-Brandenburg Center for Regenerative Therapies under the mentorship of Georg Duda. There, I worked on biomaterial-based approaches to skeletal muscle regeneration, studying how engineered microenvironments influence stem cell behavior and tissue repair. This experience grounded me in biomechanics and translational research, and it reinforced an early intuition: meaningful surgical innovation often depends on understanding and manipulating the developmental and regenerative programs that precede operative intervention. As my interests in form and identity deepened, I sought perspectives beyond the laboratory. During my time at Harvard University while visiting with an ERP scholarship, I completed a master's degree in medical anthropology, focusing on concepts of physical identity and embodiment in Plastic Surgery. Studying how patients experience facial difference, reconstruction, and visibility expanded my understanding of craniofacial

conditions beyond anatomy alone. It clarified for me that craniofacial surgery is not only about restoring structure, but also about navigating deeply human questions of recognition, intimacy, normalcy, and identity.

These parallel interests converged most fully when I entered the field of craniofacial developmental biology. As a Shriner Postdoctoral Fellow in Boston, I trained in the laboratory of Eric Liao, where I was immersed in neural crest biology, craniofacial genetics, and stem-cell-based disease modeling. Using patient-derived induced pluripotent stem cells, I studied rare craniofacial syndromes such as frontonasal dysplasia and cherubism, dissecting how specific genetic variants alter neural crest cell migration, differentiation, and tissue patterning. This work made explicit what had drawn me to the field all along: craniofacial anomalies are developmental phenomena first and surgical problems second. Understanding their origins is essential to improving how we treat them. In a collaboration with the University of Bonn, I pursued doctoral training in genetics under the tutelage of Kerstin Ludwig. Now in its final stages, this training strengthened my ability to move between genotype and phenotype, and to think critically about how genetic

information should and should not be utilized in clinical decision-making. It also underscored the heterogeneity of craniofacial conditions, even within nominally similar diagnoses, a theme that continues to shape my current research.

My clinical training in Plastic and Reconstructive Surgery at the University of Pittsburgh was a dream come true and has provided the complementary perspective I hoped for: how developmental insights meet the realities of operative care, longitudinal follow-up, and multidisciplinary decision-making. Caring for children and families affected by craniosynostosis, cleft lip and palate, and complex facial differences at our local Children's Hospital has reinforced the importance of precision (both technical and conceptual) in my mind and spurred my motivation to continue onwards with both clinical and research training, though this can be exceptionally exhausting.

Most recently, I was lucky enough to have the support and opportunity to expand my training into machine learning, working with Jesse Goldstein at my home institution, to learn about the construction of computational tools for quantitative craniofacial phenotyping. Using large-scale imaging datasets, we

apply unsupervised and supervised learning approaches to better characterize craniofacial shape variation and link it to a variety of outcomes. The Plastic Surgery Foundation supported my first principal investigator-led grant this academic year, enabling work on shape-modeling approaches for murine craniofacial phenotyping designed to increase analytic yield and reduce unnecessary animal use. Looking back, my path to Craniofacial Surgery has by no means been linear. Developmental biology, tissue engineering, genetics, anthropology, and machine learning have each offered different lenses on the same central question: how faces form, differ, and can be

repaired with intention and respect. I am deeply grateful to the mentors who encouraged intellectual breadth alongside surgical rigor, and to the craniofacial community, particularly through organizations like ISCFS, that values and supports cross-disciplinary thinking.

As I continue my training, my goal is to contribute to a future of Craniofacial Surgery as a Surgeon-Scientist in a way that is biologically informed, quantitatively precise, and attentive to the lived experiences of patients. The face remains, to me, one of the most compelling frontiers in medicine: where development, technology, culture, and humanity meet.



Figure 1 - Pitt Plastics Residents Celebrating the Holidays.



Figure 2 - The Liao Lab hard at work at the Annual PSRC meeting in Baltimore.

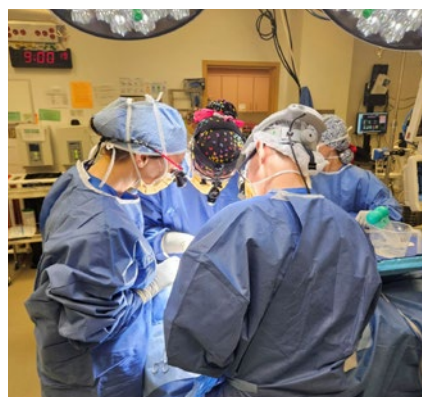

Figure 3 - Teamwork makes the dream work at the Children's Hospital of Pittsburgh



Figure 4 - Happy to participate in the Congress in Shanghai



# YOUNG SURGEONS' EXPERIENCE

## LEARNING PLASTIC SURGERY THROUGH THE WORK OF TESSIER

*"What struck me was that Tessier achieved world-leading results by today's standards, but without any of today's research and knowledge"*



**HANNA LIF**  
SWEDEN



Earlier this year, I received a once-in-a-lifetime request: **"There are stored medical records from Tessier in a library at Necker that need to be moved soon. Could you review them to see what might be publishable?"**

What I found was unlike anything I'd seen before: more than a thousand of Tessier's patient records spanning the 1950's to the 1990's - everything from rare, intricate cases to routine ones, heartfelt thank-you notes from families, amazing surgical drawings. Standing in front of the sheer volume of material, I felt as if I had stepped into an enormous, dimly lit archive where treasures were scattered everywhere, hidden

among collapsed stacks and water-damaged folders.

I had one main personal mission: to find **Tessier's early hypertelorism cases**. I wanted to understand how it all began: how he reasoned in his operative notes, what patterns emerged, what a young surgeon like me could learn from the very beginnings of modern craniofacial surgery. And, remarkably, I was lucky enough to study fifty-two of Tessier's hypertelorism cases.

From these cases, I learned about his surgical variations, why and when he modified his techniques, how he approached age at surgery, his strategies for facial and horizontal osteotomies, his



handling of canthopexies, his aesthetic reasoning, his outcomes, and how his thinking evolved over time. Findings that will be shared in a peer-reviewed paper (hopefully in 2026). After reviewing thousands of cases, I ended up scanning more than 17,000 pages from 209 complex cases for publication: craniofacial clefts (including his enthusiastic treatment of his very first no. 7), extremely rare syndromes (even found one patient treated by both Whitaker and Tessier), craniosynostosis (showing how he recognized and managed syndromes long before many were formally described), and - of course - his astonishing outcomes and what we can learn from them. What struck me was that Tessier achieved world-leading results by today's standards, but without any of today's research and knowledge, sophisticated imaging or preoperative planning - only X-rays and his own mind. A powerful reminder to those of us at the beginning of our careers: **think for yourself, train the clinical eye, rely on judgment.**

Tessier was an **early adapter of technological solutions**. Long before industry led preoperative planning, he printed tomographies slice by slice in plastic and put them together, he developed wax dolls of complex cases. His efforts in creating the right conditions for successful outcomes - for every patient - were remarkable. The work and teaching points of Tessier's legacy have been thoroughly described by others. Importantly, Tony Wolfe summarised the work of Tessier in two comprehensive books: *A man from Heric*, volumes 1 and 2. Benjamin Guichard accomplished a PhD on Tessier's work. Wolfe, Guichard and other important writers on Tessier's work all describe **the endless preparation and**



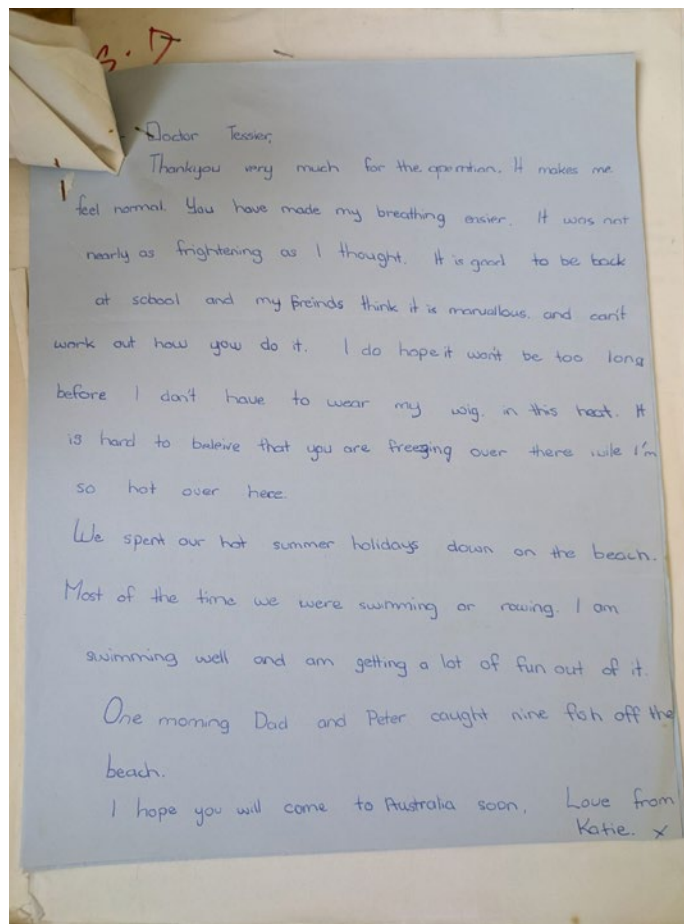
#### **efforts to perfect the treatment and outcome for every patient.**

I ended up not only learning what I expected to learn from Tessier: hypertelorism, Le Fort III, craniofacial clefts. Beyond that, I uncovered his impressive breadth of surgical skills. As I sorted the medical records into categories, the stacks told their own story: the burn cases rose into a tower; the breast cases formed a heavy block; the facelift pile grew taller and taller. And the hypertelorism pile - the one I had been most excited about - was surprisingly small in comparison. It became apparent:

**this pioneer of craniofacial surgery had amassed a vast surgical repertoire throughout his career.** His mastery didn't come from staying in one corner of the specialty, but from continuing to practice across its full landscape. Tessier's legacy becomes a lesson for any young surgeon: you can't expect to understand a surgical field by searching only for its rarest gems - you have to walk the whole terrain. **Pourquoi pas? might partly be about believing that luck can happen - but it is far more about creating the conditions in which luck matters.** Tessier showed that innovation arises

from a long, disciplined journey: years of building surgical skill, judgment, and technique through steady, everyday work combined with adapting to new technologies and knowledge. Tessier operated all the time - he didn't just wait for complex craniofacial cases. Even in other fields, highly gifted people have a very high output: the most successful mathematicians also produced the most publications; the most lauded singers were known for having hundreds of recorded and never released songs. For any young surgeon, volume is essential: it's comfortable getting used to doing little, but it comes with the price of developing hesitation to take on any challenge.

Becoming a pioneer in developing new and potentially risky surgical treatment methods for complex conditions is in many ways an act of bravery, but developing true mastery takes far more than hoping for a fortunate moment. It is the slow and deliberate process of practicing methods, cultivating patience, and gaining perspective. It might be like charting a vast and unfamiliar landscape while searching for one significant landmark that will revolutionise your field. And for Tessier, that landmark was there - not because he stumbled upon it, **but because he had spent years creating the conditions in which excellence could happen.** Not just once, but on a regular basis.



Letter from a Crouzon patient after Tessier treated her with a Le Fort III advancement.

Thank you to Professor Roman Khonsari, Dr Eric Arnaud and Dr Giovanna Paternoster at Necker for the honor of learning plastic surgery through the work of Tessier as a young (and arguably underservant) surgeon. Thank you for this once in a lifetime project, for great mentorship, and for helping to extract the learning points from

complex cases. Thank you to Dr Frank Renouard for transferring the Tessier files to the team at Necker, and to Dr Elle Vandervord for helping to move the files. Thank you also to Dr Michael Alperovich at Yale for sharing his passion for plastic surgery history, for taking part in the project and for the discussions on Tessier's legacy.

## COMMENT

This outstanding article by Dr. Hanna Lif highlights the power of curiosity, initiative, and thoughtful reflection early in a surgical career. By engaging directly with Paul Tessier's original records, Hanna transforms history into practical lessons that remain deeply relevant for young craniofacial surgeons today. Her contribution is a reminder that the ISCFS newsletter is a platform for young surgeons to share meaningful experiences, ideas, and work that shape our field. We strongly encourage you and others to follow her lead and submit articles: your perspective matters, and your voice belongs here.

*Ben Massenburg, Chair, Young Surgeons' Committee*



# NEXT **WEBINAR** TOPIC – MARCH

Onlay cranioplasty for skull contour deformities

March 24<sup>th</sup> 2026 | 11:00 am UTC

Join us on March 24<sup>th</sup> 2026,  
at 11:00 am UTC for an in-depth discussion.



## ISCFS NEWSLETTER

Volume 3 | Number 1

**MEMBERS!** Please write  
an article for

**MY WAY:**

**Reconstructive onlay  
cranioplasty**

To submit an article of 750-1000 words with up to 5  
JPG images as needed, send it to [admin@iscfs.org](mailto:admin@iscfs.org)  
no later than Friday, March 13, 2026.



APRIL 2026

# NEUROSURGERY CORNER



**JAY JAYAMOHAN**  
Neurosurgery Editor  
UNITED KINGDOM

---

*"However, as we are all at pains to say, our patients are not the same as each other, and indeed in the cohort of patients who are syndromic, are very much different from each other."*

The recent ISCFS Congress in Shanghai that many of us attended was a great opportunity to share experience and ideas. As one of the smaller contingent than usual of neurosurgeons, I was struck, as I often am, by the number of presentations that went along the title names of 'How I do' or 'Our technique', or the 'St. Elsewhere unit protocol four.' Now these were interesting and often educational, both in positive and negative ways, and gave some ideas that we will consider in our unit in Oxford. Indeed, my team have also given presentations using titles such as the 'Oxford Technique' and similar for procedures. And learning how to do a procedure by repeatedly doing it, has got significant advantages for patients. It is well recognized that, a bit like Henry Ford's manufacturing ideas (see also Toyota and cataract surgery in the USSR), doing the same procedure, on a predictable pathology, repeatedly, will lead to better outcomes, albeit alongside a slightly bored surgeon.

However, as we are all at pains to say, our patients are not the same as each other, and indeed in the cohort of patients who are syndromic, are very much different from each other even with the same genetic change. This is again where the idea of a multidisciplinary team comes into

focus to be able to look at the individual aspects of each patient, before considering what treatment is right for this particular child, as compared to the last child that has a very similar, but ever so slightly different, clinical presentation.

I had a few somewhat lively debates with a few of my neurosurgery colleagues who use techniques that are somewhat different from mine. Some were VERY different - like making a conscious decision to use a perforator to make burr holes rather than a matchstick. One of them said that they didn't want to use this, and they used a matchstick in their neurosurgery cases, but that the plastic surgery teams insisted they use a perforator because 'this was how it was done' in that unit. I would fundamentally disagree with following such a rigid protocol even when it is not the preferred one for that surgeon or group of surgeons. We are all very much responsible for our actions in theatre, and there needs to be enough flexibility to allow for different approaches. Ironically, this team's non-neurosurgery members had spearheaded quite significant changes in techniques for more plastic surgery parts of procedures - so there seems to be quite the interesting family dynamic going on!



At the risk of sounding like a broken record (for the younger readers, imagine a massive compact disc - and if you don't know what that is, then lord help me), it is why it is so important to have neurosurgeons front and centre as part of the craniofacial team. The preoperative assessment, review of the scans, and discussion with the accompanying reconstruction surgeon who will do the case with us is so important to be able to work out what the risks are of any particular procedure, and whether there is a safer alternative that will give the same or sometimes slightly inferior appearance related outcomes, but with a much safer risk profile.

This cannot be done, again as I've said before, if the surgeon simply rocks up to the operating theatre,

looks at the scan for the first time, and makes a plan, or even worse, simply looks at the markings made on the head. The advent and increasing use of endoscopic or spring assisted surgery will, I think, make this even more important since increasing proportions of this operation will be handled from a planning side by neurosurgeons as opposed to plastics or maxillofacial surgeons.

Therefore, this is again another call to arms to my neurosurgical colleagues to push themselves further into the teams that look after craniofacial patients in their units, and also to join this society if they are able to so that at some point, we will fill up a big chunk of the hall at a meeting - perhaps in Rotterdam in 2027.

TLDR\*: Attributed to Lao Tzu - 'the green reed which bends in the wind is stronger than the mighty oak which breaks in a storm.'

Agree? Disagree? Bored of me behaving like a crazy guy shouting things on a street corner? Please, for the love of all good things - send in a neurosurgery related article for the next edition. Otherwise, the Oxford protocol for this column will continue unabated for another 2 long, long years...

*\*Editor's note: I had to look it up. Too Long, Didn't Read.*



## WELCOMING THE ISCFS GLOBAL SUPPORTER FOR 2026

**We are proud to welcome our global supporter for 2026 and extend our heartfelt thanks for their invaluable contribution to our society.**

**Their commitment helps us advance education, innovation, and excellence across the field. Together, we look forward to another impactful year.**



**GOLD GLOBAL SUPPORTER**

**Johnson & Johnson  
MedTech**

# ORTHODONTIC CORNER

## INTEGRATED ORTHODONTIC AND SURGICAL MANAGEMENT IN SYNDROMIC CRANIOSYNOSTOSIS: CASE REPORT OF APERT AND CROUZON SYNDROMES



**HITESH KAPADIA**  
UNITED STATES



**MARIELENA LAYUNO MATOS**  
UNITED STATES



**SRINIVAS SUSARLA SRINIVAS**  
UNITED STATES



**RICHARD HOPPER**  
UNITED STATES

### ABSTRACT

Syndromic craniosynostosis is characterized by premature fusion of cranial sutures, leading to complex craniofacial anomalies and functional impairments. These patients require long-term, multidisciplinary care due to airway, neurological, and musculoskeletal challenges. This case report describes the orthodontic and surgical management of two patients—one with Apert syndrome and the other with Crouzon syndrome. Both cases involved staged orthodontic treatment and multiple surgical interventions, including distraction osteogenesis and orthognathic surgery. The report highlights the importance of coordinated, long-term interdisciplinary care in achieving

optimal outcomes for patients with syndromic craniosynostosis.

### INTRODUCTION

Craniosynostosis is defined as the premature fusion of one or more cranial sutures, resulting in abnormal craniofacial growth, increased intracranial pressure and associated neurodevelopmental impairment<sup>1</sup>. The condition occurs in approximately 1 in 2,000-2,500 live births worldwide<sup>2</sup>. Clinical presentation varies depending on the number and location of fused sutures<sup>1,3</sup>.

Craniosynostosis is broadly classified as syndromic or non-syndromic. Syndromic craniosynostosis arises from genetic mutations that affect cranial

development and other organ systems, leading to abnormalities involving neurological, respiratory, cardiovascular, musculoskeletal and sensory functions. Among the most common forms are Apert and Crouzon syndromes, both associated with mutations in the FGFR2 gene, but differing in their clinical and craniofacial manifestations<sup>1,4</sup>.

Patients with syndromic craniosynostosis often require long-term, multidisciplinary management to address esthetic, functional and psychosocial concerns. The present case reports describe comprehensive orthodontic and surgical management of patients with Apert syndrome and Crouzon syndrome—emphasizing interdisciplinary coordination and staged treatment planning.

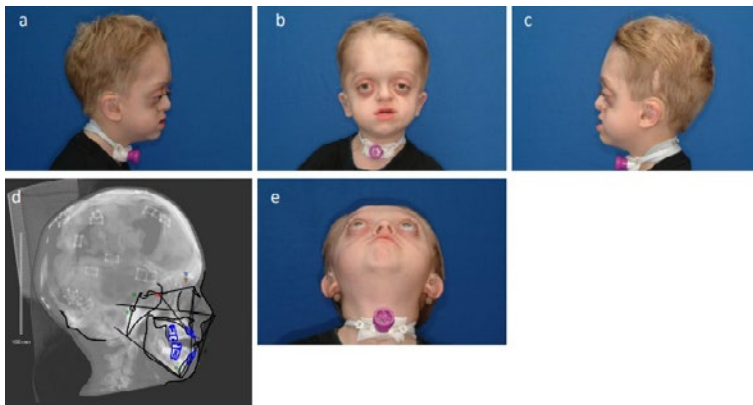


Figure 1. Case 1 - 5-year-old male with Crouzon syndrome. (a, b, c, e) Initial facial photographs and (d) lateral cephalometric radiographs.

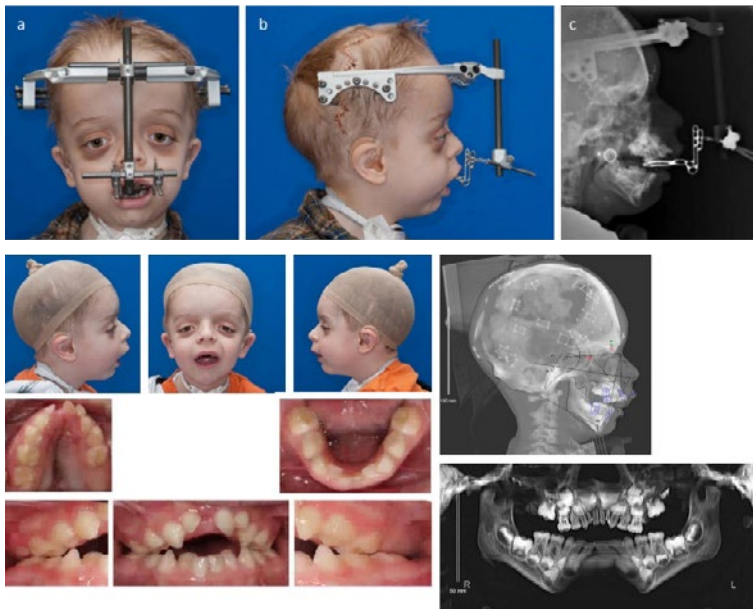


Figure 2. Case 1 - 6 years of age. (a, b, c) Facial photographs and a lateral cephalometric radiograph obtained during the consolidation phase of Le Fort III distraction osteogenesis (DO). (d) Clinical photographs and radiographs following removal of appliances and prior to beginning limited orthodontic treatment.

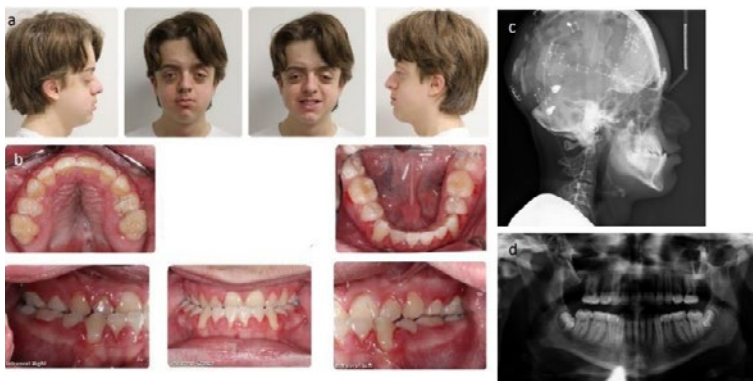

Figure 3. Case 1 - 14 years of age. (a, b, c, d) Final orthodontic records obtained following limited orthodontic treatment involving rapid palatal expansion and the extraction of lower first premolars.

## CASE REPORTS

### Case 1: Crouzon syndrome -

A 5-year-old male with Crouzon syndrome, followed since birth, presented with concerns of brachycephaly, frontal bossing, cranial defects secondary to prior intracranial hypertension, ocular hypertelorism with bilateral proptosis and midface hypoplasia. There was also severe obstructive sleep apnea, requiring tracheostomy for airway management (Figure 1 a, b, c, d, e).

Radiographic evaluation showed midface hypoplasia and associated Class III skeletal malocclusion with a vertical growth pattern and divergent palatal and mandibular occlusal planes (Figure 1 d). Intraoral examination showed a high-arched palate and severe dental crowding.

Based on clinical presentation, the patient was considered a candidate for midface advancement via Le Fort III osteotomy with distraction osteogenesis (DO). At six years of age, Le Fort III DO was performed using an external distractor (Figure 2 a, b, c). This resulted in improvement in inferior orbital rim position and a more favorable airway, permitting decannulation (Figure 2 d).

At 14 years of age, the patient underwent a limited phase of orthodontic treatment to address maxillary constriction and relieve dental crowding through rapid palatal expansion (RPE) and extraction of the upper and lower first premolars (Figure 3 a, b, c, d). Notably, the maxillary second and third molars failed to develop, likely due to disruption during the distraction procedure (Figure 3 d).

Upon reaching skeletal maturity, comprehensive preoperative orthodontic treatment was initiated to optimize dental alignment and eliminate compensations (*Figure 4 a, b, c*). The patient subsequently underwent Le Fort I maxillary osteotomy with genioglossus advancement, improving skeletal and occlusal relationships and alleviating residual sleep-disordered breathing. Postoperatively, orthodontic treatment continued to refine the occlusion. The total treatment duration was two years (*Figure 5 a, b, c, d*).

#### Case 2: Apert syndrome -

A 13-year-old female with Apert syndrome presented to the Craniofacial Team for evaluation after receiving prior treatment elsewhere. Clinical examination revealed acrocephaly, mild frontal bossing, ocular hypertelorism, midface and nasomaxillary hypoplasia with associated facial concavity, and characteristic hand anomalies. Intraoral evaluation was notable for a high-arched palate, severe maxillary constriction, dental crowding, and an Angle Class III malocclusion with an anterior open bite (*Figure 6 a, b*).

The panoramic radiograph demonstrated absence of the upper and lower permanent canines and the upper right first premolar. The lateral cephalometric radiograph showed a skeletal Class III relationship with a vertical growth pattern (*Figure 6 c, d*).

At 14 years of age, the patient

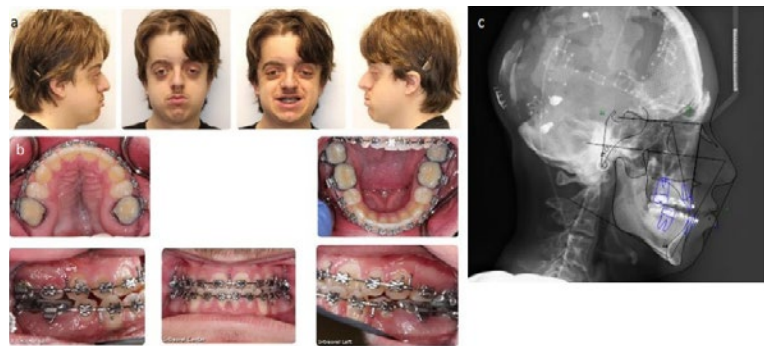


Figure 4. Case 1 - skeletal maturity. (a, b, c) Presurgical orthodontic records taken after initiation of comprehensive pre-surgical orthodontic treatment.

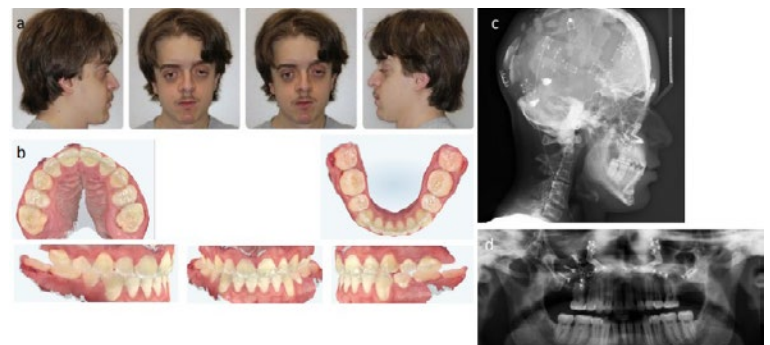


Figure 5. Case 1 - completion of orthodontic treatment. (a, b, c, d) Final orthodontic records following orthodontic treatment and a Lefort I maxillary advancement with genioglossus advancement.

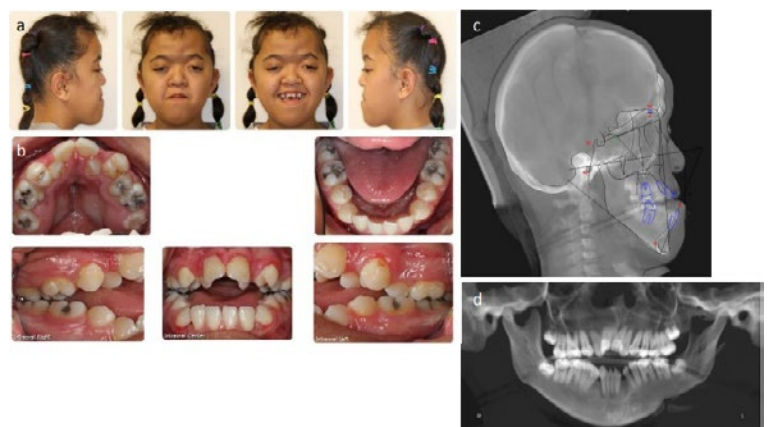


Figure 6. Case 2 - 13-year-old female with Apert syndrome. (a, b) Initial facial photographs and (c, d) radiographs.



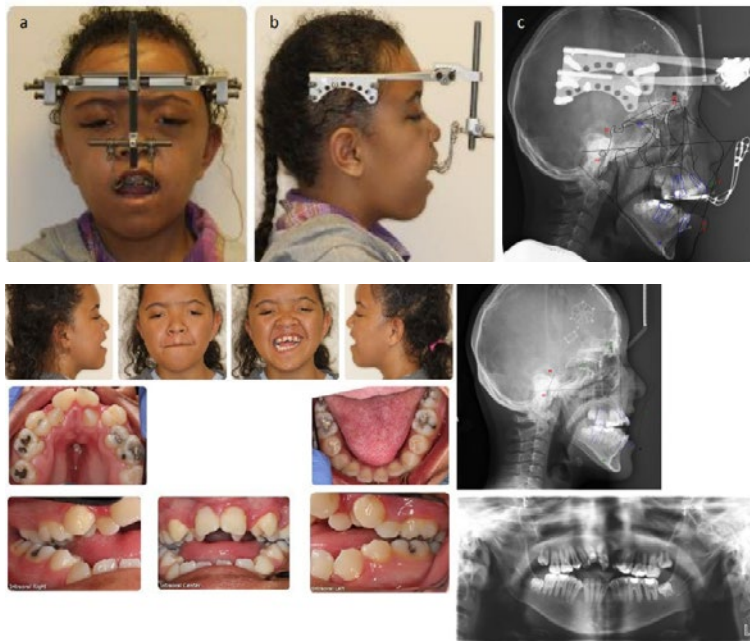


Figure 7. Case 2 - 14 years of age. (a, b, c) Facial photographs and lateral cephalometric radiograph obtained during the activation phase of the Le Fort II DO with zygomatic repositioning. (d) Orthodontic records taken after removal of distraction appliances.

underwent Le Fort II DO and zygomatic repositioning (LF2ZR). The objectives of this procedure were to differentially advance the zygomas and midface, while increasing upper facial height through a downward and forward distraction vector (Figure 7 a, b, c, d).

Following midface distraction, comprehensive orthodontic treatment was initiated to relieve dental crowding, establish proper incisor inclination, and coordinate the arches in preparation for definitive orthognathic surgery (Figure 8 a, b, c, d).

At skeletal maturity (18 years),

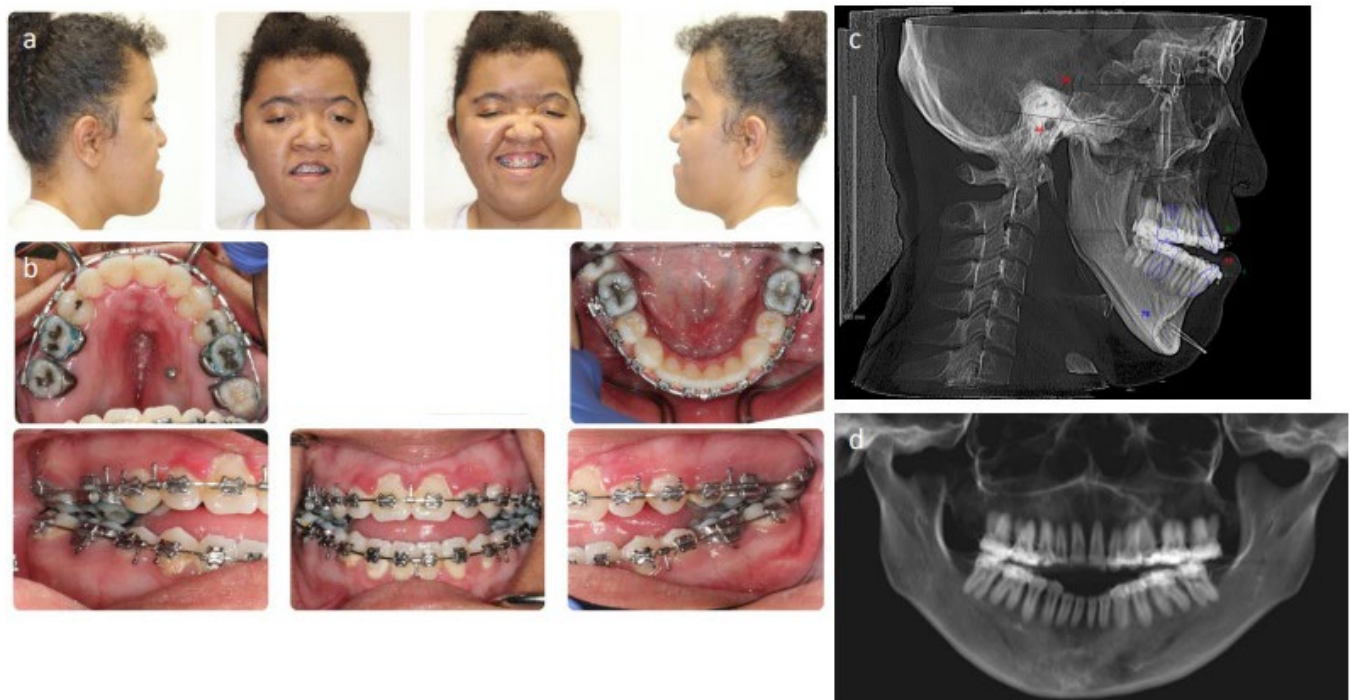


Figure 8. Case 2 - skeletal maturity. (a, b, c, d) Presurgical records taken after initiation of comprehensive orthodontic treatment.

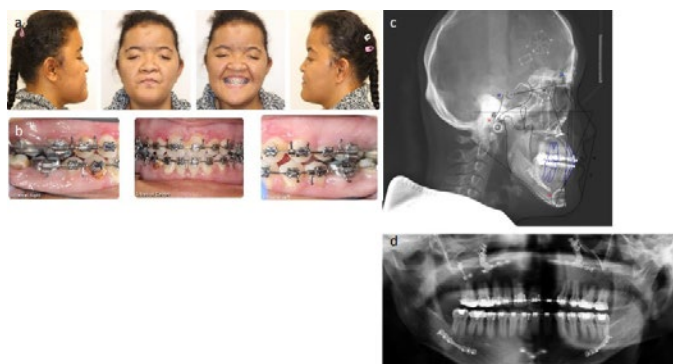


Figure 9. Case 2 - 18 years old. (a, b, c, d) Postsurgical orthodontic records taken after Le Fort I maxillary advancement with posterior impaction and bilateral sagittal split osteotomies (BSSO) with counterclockwise mandibular rotation and genioplasty.

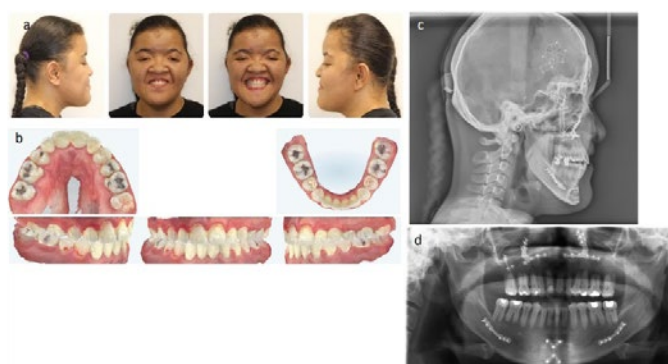


Figure 10. Case 2 - completion of orthodontic treatment. (a, b, c, d) Final orthodontic records obtained following comprehensive orthodontic and surgical treatment.

the patient underwent bimaxillary orthognathic surgery consisting of Le Fort I maxillary advancement with posterior impaction and bilateral sagittal split osteotomies (BSSO) with counterclockwise mandibular rotation and genioplasty (Figure 9 a, b, c, d). Final orthodontic treatment focused on achieving a stable occlusion. No concerns for obstructive sleep apnea were identified postoperatively (Figure 10 a, b, c, d)

## DISCUSSION

In this review, we highlight the orthodontic-surgical collaboration integral to managing cases of syndromic craniosynostosis. Patients with Apert or Crouzon syndrome present with skull deformities, digit anomalies and substantial orthodontic needs resulting from hypodontia, ectopic eruption, dental crowding and increased caries risk <sup>5</sup>. A characteristic skeletal Class III malocclusion related to midface deficiency—more pronounced in the central midface in Apert syndrome—along with severe palatal constriction or cleft palate, further

necessitates early orthodontic intervention <sup>4</sup>.

Formal orthodontic assessment begins at 5-6 years of age, with care spanning through adulthood. Early intervention centers on periodic growth assessments, guidance on the timing of surgical procedures, active space management for the developing dentition and the use of RPE. In Case 1, the first phase orthodontic treatment included RPE and space management <sup>5</sup>.

During early development, midfacial surgical intervention may be considered depending on the clinical severity, airway status, and the need for orbital protection. In cases involving increased intracranial pressure and hypertelorism, advancement of the frontal bone and midface by monobloc DO may be considered. In the absence of the above findings, options for sub-cranial advancement include Le Fort III or Le Fort II osteotomies, with or without zygomatic repositioning, performed alone or in

combination with DO <sup>6</sup>. Le Fort III DO remains the standard approach for correcting midface hypoplasia extending to the frontozygomatic region, enabling symmetric advancement of the nasomaxillary-zygomatic complex and improving midface projection, ocular stability, and airway volume. External distraction allows more controlled and stable skeletal movement <sup>7-8</sup>. Case 1 involved Le Fort III DO with resulting improvement in facial proportions and airway function.

More recently, Le Fort II DO, combined with zygomatic repositioning (LF2ZR), has been used for Apert syndrome. Because there is disproportionately more severe central midface hypoplasia relative to zygomatic deficiency, LF2ZR allows differential correction of central and lateral midfacial components <sup>9</sup>. This approach was used successfully in Case 2.

Despite early midface advancement, maxillary hypoplasia and malocclusion often persist at skeletal maturity, necessitating

definitive correction <sup>6</sup>. Orthodontic preparation at this stage focuses on leveling the arches, decompensating dental inclinations and coordinating transverse and sagittal relationships <sup>5</sup>. Surgical procedures may include multi-piece Le Fort I osteotomy for maxillary advancement and expansion, BSSO, genioplasty and adjunctive procedures such as rhinoplasty or bone grafting. Postoperative orthodontic detailing and long-term retention protocols follow, as demonstrated in both Cases 1 and 2. Overall, optimal outcomes in

syndromic craniosynostosis rely on interdisciplinary collaboration throughout diagnosis, treatment planning, surgical execution, and postoperative follow-up. This coordinated approach ensures functional, esthetic, and airway improvements that remain stable over time.

### CONCLUSION

The surgical and orthodontic techniques involved in treating syndromic craniosynostosis require thorough diagnosis, treatment planning, and clinical

management <sup>10-11</sup>. The combination of different surgical alternatives and orthodontic treatment, along with multidisciplinary collaboration between both disciplines, produced excellent outcomes for both patients.

## REFERENCES

1. Shin, K., Moreno-Urbe, L. M., Allareddy, V., Burton, R. G., Menezes, A. H., Fisher, M. D., Weber-Gasparoni, K., & Elangovan, S. (2020). Multidisciplinary care for a patient with syndromic craniosynostosis: A case report with 20 years of special care. *Special Care in Dentistry*, 40(1), 127-133. <https://doi.org/10.1111/scd.12437>
2. Betances EM, Mendez MD, & Karsonovich T. (2025). Craniosynostosis. StatPearls.
3. Nurko, C., & Quinones, R. (2004). Dental and orthodontic management of patients with Apert and Crouzon syndromes. *Oral and Maxillofacial Surgery Clinics of North America*, 16(4), 541-553. <https://doi.org/10.1016/j.coms.2004.08.003>
4. Katouni, K., Nikolaou, A., Mariolis, T., Protogerou, V., Chrysikos, D., Theofilopoulou, S., & Filippou, D. (2023). Syndromic Craniosynostosis: A Comprehensive Review. *Cureus*. <https://doi.org/10.7759/cureus.50448>
5. Vargervik, K., Rubin, M. S., Grayson, B. H., Figueroa, A. A., Kreiborg, S., Shirley, J. C., Simmons, K. E., & Warren, S. M. (2012). Parameters of care for craniosynostosis: Dental and orthodontic perspectives. *American Journal of Orthodontics and Dentofacial Orthopedics*, 141(4 SUPPL). <https://doi.org/10.1016/j.ajodo.2011.12.013>
6. Buchanan, E. P., Xue, Y., Xue, A. S., Olshinka, A., & Lam, S. (2017). Multidisciplinary care of craniosynostosis. In *Journal of Multidisciplinary Healthcare* (Vol. 10, pp. 263-270). Dove Medical Press Ltd. <https://doi.org/10.2147/JMDH.S100248>
7. Hopper, R. A., Kapadia, H., & Susarla, S. M. (2020). Surgical-Orthodontic Considerations in Subcranial and Frontofacial Distraction. *Oral and Maxillofacial Surgery Clinics of North America*, 32(2), 309-320. <https://doi.org/10.1016/j.coms.2020.01.005>
8. Reitsma, J. H., Ongkosuwito, E. M., Buschang, P. H., Adrichem, L. N. A. v, & Pahl-Andersen, B. (2013). Craniofacial Stability in Patients with Crouzon or Apert Syndrome after Le Fort III Distraction Osteogenesis. *The Cleft Palate Craniofacial Journal*, 50(5), 561-569. <https://doi.org/10.1597/12-013>
9. Hopper, R. A., Kapadia, H., & Susarla, S. M. (2018). Le Fort II Distraction With Zygomatic Repositioning: A Technique for Differential Correction of Midface Hypoplasia. *Journal of Oral and Maxillofacial Surgery*, 76(9), 2002.e1-2002.e14. <https://doi.org/10.1016/j.joms.2018.04.02>
10. McCarthy, J. G., Warren, S. M., Bernstein, J., Burnett, W., Cunningham, M. L., Edmond, J. C., Figueroa, A. A., Kapp-Simon, K. A., Labow, B. I., Peterson-Falzone, S. J., Proctor, M. R., Rubin, M. S., Sze, R. W., Yemen, T. A., Arnaud, E., Bartlett, S. P., Blount, J. P., Boekelheide, A., Buchman, S. R., ... Wornom, I. L. (2012). Parameters of care for craniosynostosis. *Cleft Palate-Craniofacial Journal*, 49(1 SPEC. SUPPL). <https://doi.org/10.1597/11-138>
11. Zaki, H. A., Allassaf, M.S., Babkair, H. A., Abdel-Latif, G. A., Jaffar, A. K., Alolayan, A. B., & Elsayed, S. A.-H. (2022). Multidisciplinary Rehabilitation Approach to the Maxillo-Facial Complications of Crouzon's Disease: Case Report and Review. *The Open Dentistry Journal*, 16(1). <https://doi.org/10.2174/18742106-v16-e2206300>



# ISCFS WELCOMES NEW MEMBERS

New Active and Associate members were admitted by vote of current Active Members in December:

## ACTIVE MEMBERS

Philippe De Vloo, MD PhD - BELGIUM  
Titiaan Jakob Dormaar, MD DDS - BELGIUM  
Christian Oliver Duncan, MB, BCh, BAO, FRCSI, MPhil, FRCSI(Plast) - UK  
Enrico Ghizoni, MD PhD - BRAZIL  
Thomas Mon-Hsian Hsieh, MD PhD - TAIWAN  
Laura Humphries, MD - US  
Ting-Chen Lu, MD - TAIWAN  
Fabio Mazzoleni, MD - ITALY  
Maria Costanza Meazzini, DDS - ITALY  
Joseph Napoli, MD DDS - US  
Asaf Olshinka, MD - ISRAEL  
Yun Phua, FRACS - AUSTRALIA  
Jochem K. H. Spoor, MD PhD LLM - US  
Diego M. Steinberg, MD - ARGENTINA  
Siti Isya Wahdini, MD - INDONESIA

## ASSOCIATE MEMBERS

Anna R. Carlson, MD - US  
Güven Osan Kaplan, MD - TURKEY  
Joseph Lopez, MD, MBA - US  
Benjamin Massenburg, MD - US  
Mattia Moretti, MD - ITALY  
Ruth Tevlin, MB BAO BCh MRCSI MD - US  
Philip Tolley, MD - US  
Dwi Wicaksono, MD - INDONESIA

## RESIDENT/FELLOW MEMBERS ADMITTED IN 2025 – VOTE NOT REQUIRED

Zhewei Chen, MD - CHINA  
Joshua A. David, MD - CANADA  
Rhodri O. H. L. Davies, MBBS, BDS, MSc - UK  
Annie Do, MD - US  
Khalid El Ghouli, MD DMD - NETHERLANDS  
Nissia Ananda Harianto, MD - INDONESIA  
Janina K. Kueper, MD - US  
Hannah Lif, MD, PhD - SWEDEN  
Carrie Morales - US  
Arif Muharram, MD - INDONESIA  
David Perrault, MD - US  
Anika Szswedysz, MD - FINLAND  
Anna Tan, MS (Plastic Surgery), MBBS - MALAYSIA  
Lindsey Teal, MD, MPH - US  
Miika Juhani Toivari, MD, PhD, DDS - FINLAND  
Elle Vandervord, MBBS, FRACS - AUSTRALIA  
Robin T. Wu, MD - US  
Andi Zhang, MD - US  
Chunyan Zhao, MD PhD - JAPAN  
Yehong Zhong, MD PhD - CHINA

I encourage you to promote membership to your colleagues. The next vote to admit new members will be in June. The process is not difficult with on-line applications available at: <https://iscfs.org/membership/>




**JESSE TAYLOR**

ISCFS Secretary-Treasurer &  
Membership Chair  
UNITED STATES



# BECOME AN ISCFS MEMBER



We welcome membership applications in Active, Associate, Corresponding, Orthodontic, Research, and Resident/Registrar/Fellow categories and have created a simple on-line process. Current member specialties include plastic, craniofacial, oral and maxillofacial surgeons, neurosurgeons, orthodontists, otorhinolaryngologists, dentists, and those involved in related research.

There is a \$75 application fee and annual fees are \$200 for Active/Associate members and \$50 for Resident/Registrar/Fellow members. Our website includes information about qualifications for membership and frequently asked questions at this link:

<https://iscfs.org/membership/>

## MEMBERSHIP BENEFITS

- Global Visibility
- International Recognition
- Reasonable yearly membership fees
- Reduced registration fee at the biennial international ISCFS Congress
- Professional networking

## JOIN US!

ACTIVE/ASSOCIATE

RESIDENT/REGISTRAR/  
FELLOW



INTERNATIONAL  
SOCIETY OF  
CRANIOFACIAL  
SURGERY

[www.iscfs.org](http://www.iscfs.org)

# EVENT CALENDAR

## **EACMFS**

**28<sup>th</sup> Congress of the European Association for Cranio Maxillo Facial Surgery**

Location: Athens, Greece

Date: September 15-19, 2026

Website:

[www.eacmfs-congress.com](http://www.eacmfs-congress.com)

## **ESCFS**

**European Society of Craniofacial Surgery Congress**

Location: Ankara, Türkiye

Date: September 17-19, 2026

Website:

[www.escfs2026.org](http://www.escfs2026.org)

## **ACPA'S**

**American Cleft Palate-Craniofacial Association 2026 Annual Meeting**

Location:

Hilton Boston Park Plaza

Boston, MA, USA

Date: March 24-28, 2026

Website:

[acpacares.org/annual-meeting](http://acpacares.org/annual-meeting)

## **ISCFS 2027**

Location: Rotterdam, Netherlands

Date: September 7-10, 2027

Website: [www.iscfs.org](http://www.iscfs.org)

To submit a meeting to the calendar in our next issue, send the following information to [admin@iscfs.org](mailto:admin@iscfs.org): Meeting Title, Location, Dates, Website.

## ISCFS MANAGEMENT

### ISCFS COUNCIL

**IRENE MATHIJSSSEN**, Netherlands - President  
**CASSIO E. RAPOSO DO AMARAL**, Brazil - Co-Vice President  
**NIVALDO ALONSO**, Brazil - Co-Vice President  
**JESSE TAYLOR**, United States - Secretary-Treasurer  
**XIONGZHENG MU**, China - Immediate Past President  
**JAY JAYAMOHAN**, United Kingdom - Council, Neurosurgery  
**CATHERINE LEE**, Singapore - Council, Orthodontics  
**JONG-WOO CHOI**, Korea - Council  
**ROMAN KHONSARI**, France - Council  
**MARK URATA**, United States - Council  
**ERIC ARNAUD**, France - Parliamentarian  
**BEN MASSENBURG**, United States -  
Young Surgeons' Representative (New Council Seat)

### ISCFS SOCIETY MANAGEMENT TEAM

**BARBARA BOELD**, Germany - Executive Director  
**CATHERINE FOSS**, United States - Administration  
**VERENA REINMUTH**, Germany - Administration



**INTERNATIONAL  
SOCIETY OF  
CRANIOFACIAL  
SURGERY**

#### LEGAL ADDRESS

Hub 11571  
3401 Civic Center Blvd  
Philadelphia, PA 19104  
United States

#### MAILING ADDRESS

**US:**  
38 Rayton Road  
Hanover, NH 03755 USA

#### EUROPE:

Reitmorstrasse 25  
80538 Munich, Germany

**US email:** [admin@iscfs.org](mailto:admin@iscfs.org)

**Europe email:** [office@iscfs.org](mailto:office@iscfs.org)

[www.iscfs.org](http://www.iscfs.org)



## ISCFS NEWSLETTER EDITORIAL BOARD

### EDITOR

**JESSE TAYLOR**, United States

### MANAGING EDITOR

**CATHERINE FOSS**, United States

### GRAPHIC DESIGNER

**DORIS SCHUBERT**, Germany

### NEUROSURGERY EDITOR

**JAY JAYAMOHAN**, United Kingdom

### ORTHODONTICS EDITOR

**MARIANA SABÁS**, Argentina

### HISTORY EDITOR

**RICCARDO MAZZOLA**, Italy

### EXECUTIVE DIRECTOR

**BARBARA BOELD**, Germany

---

**DISCLAIMER:** This newsletter presents information and opinions pertinent to medical professionals. It does not provide advice concerning specific diagnoses and treatments of individual cases and is not intended for use by the lay person. ISCFS is not responsible for facts, opinions, and other information presented by the authors or advertisers in this newsletter or otherwise. Readers are strongly advised to confirm that the facts, opinions, and other information comply with the latest legislation and standards of practice. ISCFS, the editors, the authors, and the publisher will not be responsible for any errors or liable for actions taken as a result of facts, opinions, and other information expressed in this newsletter or otherwise. Copyright © 2026 by the International Society of Craniofacial Surgery, Inc. All rights reserved. Contents may not be reproduced in whole or in part without written permission of ISCFS.

[www.iscfs.org](http://www.iscfs.org)

**ISCFS 2027**

INTERNATIONAL SOCIETY OF CRANIOFACIAL SURGERY

**7-10 SEPTEMBER**

**Rotterdam | Netherlands**



**SAVE THE DATE**

**The International Society of Craniofacial Surgery  
invites you to Rotterdam, Netherlands  
for the 22<sup>nd</sup> Congress on September 7-10, 2027.**



**Prof. Dr. Irene Mathijssen**  
ISCFS Congress President (Rotterdam)

**SEE YOU IN ROTTERDAM!**